

SURGICAL TREATMENT OF LARGE DIMENSIONS SIALOLITH IN SUBMANDIBULAR GLAND: CASE REPORT

Fabrcio Henrique Pereira de Souza¹, acadêmico de odontologia, Universidade Paulista, Goiânia-GO, Brasil, fabricoodontounip@hotmail.com
Cristiane Gonçalves Teixeira¹, acadêmico de odontologia, Universidade Paulista, Goiânia-GO, Brasil, cristiane@gmail.com
Cláudio Maranhão Pereira³, Doutor em Estomatopatologia – FOP/UNICAMP, Professor Titular de Estomatologia da Universidade Paulista, Goiânia-GO, Brasil, Professor de Patologia Oral, Estomatologia e Farmacologia do curso de Odontologia – ICESP/Brasília. claudiomaranhao@hotmail.com.

Autor correspondente:
Claudio Maranhão Pereira
Faculdade de Odontologia – ICESP/Brasília
Coordenação de Odontologia
QS 5 - Águas Claras, Brasília - DF, 71961-540
Brasília-DF/BRASIL
e-mail: claudiomaranhao@hotmail.com;

Declaração conflito de interesse: nada a declarar

Transferência de direitos autorais: todos os autores concordam com o fornecimento de todos os direitos autorais a Revista Ciência e Odontologia

Summary

Sialolites are calcified formations that occur in the parenchyma of the salivary glands or in their ducts. Among the salivary glands, the submandibular glands are the most affected and represent about 80% of reported cases. Sialolites larger than 15 mm are mineralizations considered rare and few cases have been described. These mineralizations require surgical removal in most cases extraorally, under general anesthesia. Cases of spontaneous expulsion can be observed, however, only in the case of small mineralizations. Although surgical removal is the treatment of choice for large mineralizations, these should be carefully planned due to the sequelae that they may cause to the patient. The maintenance of these alterations within the ductal system may lead to sialo-

denitis, hyposalivation and consequent oral microbiota imbalance favoring opportunistic fungal infections, dental caries, taste alteration among other consequences. Therefore, this study reports a case of large sialolith in a right submandibular gland surgically removed intraorally.

Keyword: Lithiasis, Submandibular Gland, Surgical Diagnostic Techniques

Abstract

Sialolites are calcified formations that occur in the parenchyma of the salivary glands or in their ducts. Among the salivary glands, the submandibular glands are the most affected and represent about 80% of reported cases. Sialolites larger than 15 mm are considered mineralizations rare and few cases have been des-

Enviado: april 2019
Revisado: june 2019
Aceito: august 2019

cribed. These mineralizations require surgical removal in most cases through the extraoral route under general anesthesia. Cases of spontaneous expulsion can be observed, however, only in the case of small mineralizations. Even though surgical removal is the treatment of choice for large mineralizations, these should be carefully planned due to the sequelae that they may cause to the patient. The maintenance of these alterations within the duc-

tal system can lead to sialadenitis, hyposalivation and consequent oral microbiota imbalance favoring opportunistic fungal infections, dental caries, taste alteration among other consequences. Therefore, this study reports a case of large sialolith in a right submandibular gland surgically removed intraorally.

Key words: Lithiasis, Submandibular Gland, Surgery Diagnostic Techniques

INTRODUCTION

Sialolithiasis is a pathology characterized by the presence of mineralized structures within the ductal system of major or minor salivary glands^{1,2}. The formation of the stone has been a specific cause and is attributed to changes in the secretion and composition of the expelled saliva, trauma, and anatomical disposition of the gland (Referência). The size of the stone is usually smaller than 10mm, but in rare cases it may exceed 15mm and is characterized as giant stone^{3,4,5}. The incidence of symptomatic salivary stones is 59 cases per million per year, being more common among male patients with peak incidence between 30 and 60 years of age^{6, 7,8}. A sialolithiasis is responsible for more than 50% of the disease of the larger salivary glands and is therefore the most common cause of chronic infections⁹.

For the diagnosis of sialolithiasis, the clinical examination must be associated with the radiographic examination^{1, 10}. Its treatment depends on the analysis of its characteristics, since smaller calculi when located inside the ducts can be removed by the milking maneuver. Those with larger dimensions can be removed through intraoral or extraoral access depending on the location, shape and size of the stone¹¹.

Therefore, the aim of this study is to report a case of a large sialolith surgically removed.

CASE REPORT

Male, R. L. F., 48 years, melanoderma, was referred for evaluation in the clinical stomatology due to alteration detected by routine orthodontic radiography. According to patient, about 2 months before, an asymptomatic and stable increased volume appeared below the tongue, did not hinder the performance of stomatognathic functions. In addition, the patient did not report pain or difficulty eating as a result of the lesion. At oral clinical examination it was possible to observe slight swelling on the floor of the oral cavity near the right submandibular gland caruncle. The lesion was consistent to palpation and had imprecise limits (Figure 1). The panoramic radiographic examination showed a circumferential radiopaque image in the anterior and right jaw region with a diameter of approximately 35 mm (Figure 2).

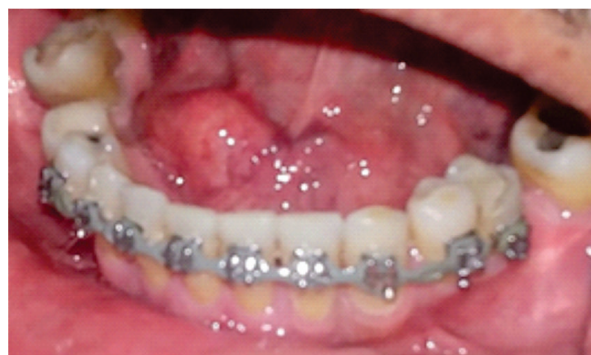

Figure 1. Examination and clinical aspect of the alteration. It is possible to observe volume increase in the buccal floor on the right side. (Crop this photo only oral cavity).

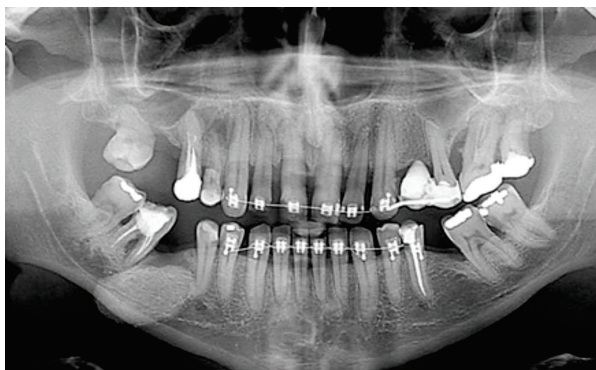


Figure 2. Panoramic Radiography. It is possible to observe radiopaque image, well delimited, with about 3 cm in its largest diameter.

Based on clinical and radiographic data, the diagnostic hypothesis of sialolith was suggested. Due to its location and size, we opted for the surgical removal of the alteration, confirming the diagnosis of sialolithiasis (Figures 3 and 4).

Currently, the patient is under clinical follow-up and, after 2 months, showed no recurrence or other local alteration.

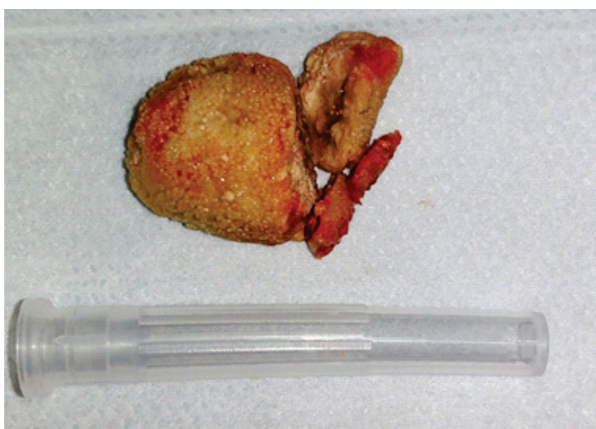


Figure 3. Macroscopic appearance of sialolith after its removal.

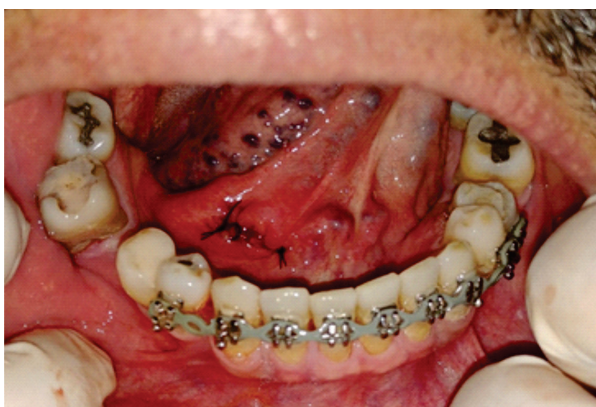

Figure 4. Clinical appearance of the site after suture.

DISCUSSION

Sialoliths are calcified structures that develop in the major salivary glands and/or their ducts, and may be associated with smaller salivary glands. In general, they are asymptomatic and slowly evolving¹². In the clinical case presented, it was possible to observe an asymptomatic increase in the buccal floor, which did not functionally disrupt the patient's stomatognathic system.

In cases of sialolithiasis, the evaluation of the radiographic examination is of greatest importance to complement the clinical examination. This exam helps in the diagnosis and guides the treatment that will be approached. The choice of treatment is directly linked to the location of the sialolith. The treatment of choice, when possible, is removal of sialolith via intraoral access. The incision in the floor of the mouth is little associated with complications, such as a salivary fistula, and allows exposure of the affected duct and visualization of the sialolith. The duct is then sutured to the oral mucosa, leaving it open for adequate drainage¹³. In this case, we proceeded like this, with no postoperative complications, such as salivary fistula, which is difficult to resolve and has an unfavorable prognosis.

CONCLUSION

The present clinical case was intended to demonstrate the diagnosis, clinical management and surgical technique for removal minimally invasive of sialolith in the submandibular gland duct, without disrupt the patient's stomatognathic functions.

BIBLIOGRAPHIC REFERENCES

1. Alves NS, Soares GG, Azevedo RS, Camisasca DR. Sialolito de grandes dimensões no ducto da glândula submandibular. *RevAssoc Paul CirDent* 2014;68(1):49-53.
2. Azenha MR, Brentegani LG, da Silva AM, Rizoli FA, de Lacerda SA, Filho OM. Sialolito de grandes proporções localizado no ducto da glândula submandibular: diagnóstico e tratamento cirúrgico. *Odontol. Clín.-Cient. (Online)* vo12 no.1 Recife Jan./Mar. 2013.

3. Alvarenga RL, Andrade R, Amaral MBF, Galizes BF, Jaeger F. Sialolito gigante no ducto da glândula submandibular. Rev. Port. Estomatol. Med. Dent. Cir. Maxilofac. 2013;54(1) 33-36.

4. Assis AF, Gabrielli MAC, Kluppel LE, Landgraf H. Extenso sialolito no ducto da glândula submandibular: relato e caso. Rev. Cir. Traumatol. Bucomaxilo-fac., Camaragibe v.6, n.2, p.29-34, 2006.

5. Miyahara GI, Silva ARS, Soares GR, Soubhia AMP. SOARES. Considerações atuais da sialolitíase de ducto de glândula submandibular. Rev. Odontológica de Aracatuba. , 2010;31(1): 46-50.

6. Lustmann J, Regev E, Melamed Y. Sialolithiasis. A survey on 245 patients and a review of the literature. Int J Oral Maxillofac Surg 1990;19:135-138.

7. Escudier MP, McGurk M. Symptomatic sialoadenitis and sialolithiasis in the English population, an estimate of the cost of hospital treatment. Br Dent J 1999;186:463-466.

8. Capaccio P, Torretta S, Ottavian F, Sambataro G, Pignataro L. Modern management of obstructive salivary diseases. Acta Otorhinolaryngol Ital 2007;27:161-172.

9. Zenk J, Benzel W, Iro H. New modalities in the management of human sialolithiasis. Minimallyinvasive therapy 1994; 3: 275-284.

10. Boynton TT, Lieblich SE. Unusual case of a sialolith: a case report. Oral Surg Oral Med Oral Pathol Oral Radiol. 2014 Jan;117(1):e9-10. doi: 10.1016/j.oooo.2012.03.020. Epub 2012 Aug 24.

11. Araújo FAC, Júnior ONF, Landim FS, Fernandes AV, Caubil AF. Tratamento cirúrgico de sialólito em glândula submandibular - relato de caso. Rev. Cir. Traumatol. Buco-Maxilo-Fac., Camaragibe v.11, n.4, p. 13-18, out./ dez. 2011.

12. Calabria MF. Sialolithiasis. Braz J Otorhinolaryngol. 1959;27:31-8.

13. Rocha AM, Santos TS, Amaral MF. Rev. Cir. Traumatol. Buco-Maxilo-Fac., Camaragibe v.11, n.4, p. 55-58, out./dez. 2011.